

Endodontic management of a mandibular second molar with five distinct root canals

Fatou Leye Benoist¹, Mouhamed Sarr^{2,*}, Khaly Bane³, Seydina Ousmane Niang⁴, Babacar Touré⁵

^{1,2,3}Professor, ^{4,5}Assistant Professor, Dept. of Odontology, Cheikh Anta Diop University, Dakar, Senegal

***Corresponding Author:**

Email: mouhamedsarr@yahoo.com

Abstract

Adequate knowledge on the root canal morphology is essential for successful root canal treatment.

Mandibular molar teeth show considerable variations in their external and internal radicular morphology that require special attention from dental practitioners to provide the best clinical outcomes for the patients.

The occurrence of three separate root canals in the distal root of a mandibular molar is uncommon. This article aims to present the endodontic management of a mandibular second molar that has five separate root canals (two root canals in the mesial roots and three root canals in the distal roots).

Keywords: Distal, endodontic treatment, mandibular molar, root canal, root canal morphology, root canal treatment.

Introduction

The success of endodontic treatment depends on the quality of shaping, cleaning and three-dimensional filling of canal system. Classically, as stated by several authors, typical canal configurations were assigned to each type of tooth.¹⁻⁴ However, anatomical variations can exist especially in molars. These variations should be taken into account during therapeutic procedures for prevention of high rate of unsealed canals and therefore low success rate.

The improvement of diagnosis tools, the use of optical aids and 3D imaging allow to reveal wide anatomical variations in the mesial and distal roots of mandibular molars.^{5,6} These anatomical features are often related to ethnicity and age.^{2,5}

In the mesial root, the common canal configurations found are two or three channels (0.4 to 18%).⁷

In the distal root, studies reporting the existence of a third canal are rare and a prevalence of 3% was noted according to studied population.

The clinical case aims to present the endodontic management of unusual canal morphology of a mandibular right second molar with five distinct canals, two in the mesial root and three in the distal root (corresponding to Vertucci type VIII) confirmed by post-obturation cone beam CT (CBCT).

Case Presentation

A 41 years old female (FK) was received in consultation at the Clinic of Conservative Dentistry-Endodontics of the Department of Odontology of the University. The patient complained of episodes of spontaneous pain radiating to the right ear and resisting to analgesics action.

Clinical examination revealed the presence of a cavity of caries in the right mandibular second molar (47) without swelling or tooth mobility. The axial

percussion of this tooth was slightly painful and the pulp vitality test with tetrafluoroethane (Pharmaethyl) was positive.

The X-ray film shows a radiolucency image stating the loss of dental substance and proximity of the mesial pulpal horn.

The diagnosis of irreversible acute pulpitis was made and the therapeutic decision was to perform a biopulpectomy.

After mandibular foramen anesthesia with 2% lidocaine solution and isolation with rubber dam and removal of the decayed dentine, endodontic access cavity preparation was performed. Four root canals have been identified, two in the mesial root (mesiovestibular (MV), mesiolingual (ML)) and two in the distal root (distovestibular (DV), distolingual (DL)). The determination of the working length was made by the radiographic method (Figure 1a). Analysis of this x-ray image revealed the existence of a third canal in the distal root between the DV and DL canals. Irrigation and lubrication were performed with 2.5% sodium hypochlorite and ethylene diamine tetraacetic acid (EDTA) (Glyde File Prep, Dentsply-Maillefer, Ballaigues, Switzerland). The canals were initially prepared using the NiTi ProTaper SX manual file (Dentsply-Maillefer, Ballaigues, Switzerland). Then, the canal preparation was conducted mechanically using Revo S files mounted on an endodontic motor (X Smart Denstply) at a speed of 400 rpm.

Mechanical instrumentation was continued up to diameter 30 for all the canals. Then, the canals were filled by the cold lateral compacting technique of Gutta percha (Fig. 1b) and the tooth restored with amalgam. A X-ray control was taken immediately after filling of root canal system followed by cone beam computed tomography (CBCT) confirming the existence of five separate canals (Fig. 1c)

After six months, no apical complications were detected. (Fig. 1d).

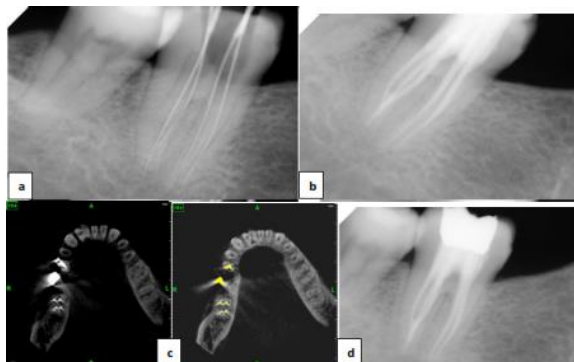


Fig. 1: a) Radiograph with files in place for working length determination ; b) Control radiograph of filling quality immediately after root canal obturation; c) Post operative CBCT image showing five canals (2 in mesial and 3 in distal position); d) Control radiograph at 6 months.

Discussion

The complete debridement of the endodontic system followed by its complete filling is an important procedure to ensure the durability of endodontic treatment. Considerable anatomical variations and complexities in the root canal are reported and require special attention during endocanal therapy.^{3,8} Hoen and Pink⁹ reported an incidence of 42% of roots and/or unsealed canals in teeth programmed for endodontic retreatment.

The purpose of this case presentation is to contribute to a better understanding of anatomical variability in the mandibular molars. This case demonstrates a rare anatomical configuration and the existence of root canal aberrations in the distal root of the mandibular molars. The distal root has three distinct root canals with three outlet gates, which could be described as a type VIII canal configuration according to the Vertucci classification.³

Cases of molars with four channels in the distal root^{10,11} or the mesial root¹² have also been reported.

Thus, it seems that absolute confidence in the predefined number of roots and/ or root canals is essential but not sufficient for the practice of endodontics.¹³ Diagnostic and therapeutic aids such as microscope or surgical glasses for root canal location^{10,13} and computed tomography (CBCT) as an adjunct to conventional radiography^{14,15} are useful for adequate endodontic therapy.

Conclusion

The root canal morphology is complex especially in mandibular molars and may exhibit some variations. It is therefore essential before undertaking endodontic treatment on these teeth to carefully evaluate the canal system for successful root canal treatment procedures.

References

1. Maggiore C, Gallottini L, Resi JP. Mandibular first and second molar. The variability of roots and root canal system. *Minerva Stomatol.* (1998) 47(9):409-16.
2. Silva EJ, Nejaim Y, Silva AV, Haiter-Neto F, Cohenca N. Evaluation of root canal configuration of mandibular molars in a Brazilian population by using cone-beam computed tomography: an *in vivo* study. *J Endod.* (2013) 39(7):849-52.
3. Vertucci FJ. Root canal morphology and its relationship to endodontic procedures. *Endod Top* (2005) 10:3-29.
4. Kim Y, Chang SW, Lee JK, Chen IP, Kaufman B, Jiang J, Cha BY, Zhu Q, Safavi KE, Kum KY. A micro-computed tomography study of canal configuration of multiple-canal mesiobuccal root of maxillary first molar. *Clin Oral Investig.* (2013) 17(6):1541-6.
5. Zhang R, Wang H, Tian YY, Yu X, Hu T, Dummer PM. Use of cone-beam computed tomography to evaluate root and canal morphology of mandibular molars in Chinese individuals. *Int Endod J.* (2011) 44(11):990-9.
6. Ozcan G, Sekerci AE1, Cantekin K, Aydinbelge M, Dogan S. Evaluation of root canal morphology of human primary molars by using CBCT and comprehensive review of the literature. *Acta Odontol Scand.* (2016) 74(4):250-8.
7. Ahmed HM, Luddin N. Accessory mesial roots and root canals in mandibular molar teeth: Case reports, SEM analysis and literature review. *Endod Pract Today* (2012) 6:195-205.
8. Ahmed HM. A paradigm evolution shift in the endodontic map. *Eur J Gen Dent* (2015) 4:98.
9. Hoen MM, Pink FE. Contemporary endodontic retreatments: An analysis based on clinical treatment findings. *J Endod* (2002) 28:834-6.
10. Baziari H, Daneshvar F, Mohammadi A, Jafarzadeh H. Endodontic management of a mandibular first molar with four canals in a distal root by using cone-beam computed tomography: A case report. *J Oral Maxillofac Res* (2014) 5:e5.
11. Arora A, Acharya SR, Sharma P. Endodontic treatment of a mandibular first molar with 8 canals: A case report. *Restor Dent Endod* (2015) 40:75-8.
12. Arunajatesan S, Krishnamurthy SK, Paramasivam V, Venkatachalam P. Management of mandibular first molar with four canals in mesial root. *J Conserv Dent.* (2013) 16(5):471-473.
13. Ahmed HM. The foremost challenge in endodontics and pediatric dentistry. *Aperito J Oral Health Dent* (2015) 1:103.
14. Ankur MB, Vandana G, Sanjay P, Jaykumar G. Endodontic management of mandibular first molar with seven canals using cone-beam computed tomography. *Contemporary clinical dentistry* (2016) 7(2):255-257.
15. Park JW, Lee JK, Ha BH, Choi JH, Perinpanayagam H. Three-dimensional analysis of maxillary first molar mesiobuccal root canal configuration and curvature using micro-computed tomography. *Oral Surg Oral Med Oral Pathol Oral Radiol Endod.* (2009) 108(3):437-42.