

Radiological and clinical assessment of pulpotomy on mature permanent molars with irreversible pulpitis: literature review

Anta Seck^{1,*}, Wendpoulomé A. D. Kaboré², Diouma Ndiaye³, Ibrahima Ndiaye⁴, Fatou Leye Benoist⁵

¹⁻³Assisrntant, ⁴PHD Student, ⁵Professor, ^{1,3,4,5}Dept. of Conservative Dentistry and Endodontics, Cheikh Anta Diop University, Dakar, Senegal, ²Dept. of Conservative Dentistry and Endodontics/Training and Research Unit in Health Sciences/ Ouaga I Professor Joseph KI-ZERBO University, Ouagadougou 03, Burkina Faso

***Corresponding Author:**

Email: anta.seck@ucad.edu.sn

Abstract

Introduction: Endodontic treatment has long been considered the only conservative therapeutic option for teeth with irreversible acute pulpitis. Histological studies have shown that the inflammation is confined to a limited surface of the pulp, near the decaying lesion, and it is not uncommon to find normal histology in the coronary pulp away from decayed surfaces as well as in roots. In dentistry, it is universally accepted that the vital pulp tissue should be preserved if possible.

Aim: The objective of this study is to review the literature on the clinical and radiographic assessment criteria for coronary pulpotomy therapeutics on mature permanent teeth with irreversible acute pulpitis.

Materials and Methods: To find relevant articles on this therapy, an electronic search strategy on PubMed, Cochran Library and Science Direct databases using the combination pulpotomy and pulpitis and permanent tooth, for indexed studies from January 2008 to April 2018.

Results: Results of this study indicated favorable success rates for this therapy. A 2018 study reported 98.4% of clinical and radiographic successes at six months. At one year, it reported 100% clinical success and 98.4% radiographic success with the use of Biodentine. Furthermore, it reported 100% clinical success and 97.5% of radiographic success rate with the use of mineral trioxide aggregate (MTA) in the first year, and 92.7% of radiograph success after three years. In 2014, a publication reported 98.19% clinical success rate with cement-enriched mixture (CEM) over a 27 month period. However, the X-ray success rates were 86.7%.

Conclusion: This treatment can be a realistic alternative for mature permanent human molars with irreversible pulpitis symptoms. But other large-scale multicentered clinical trials are strongly encouraged to substantiate this hypothesis.

Keywords: Irreversible pulpitis, Full pulpotomy, Mature permanent teeth, Permanent teeth, Pulpitis, Pulpotomy.

Introduction

Irreversible pulpitis is an inflammatory condition of the dental pulp, associated with clinical and histological signs.¹ Indeed, irreversible pulpitis are often associated with a spontaneous or lingering pain after a specific triggering, they can, sometimes, occur without symptoms.¹ In other words, correlation of clinical signs and symptoms and the pulp histopathological state is not always accurate.

Histological studies showed that the inflammation is confined to a limited area of the pulp, near the carious lesion and it is not uncommon to find a normal histology in the coronal pulp far away from carious sites and in the roots pulp as well.²

Endodontic treatment was considered the only conservative therapeutic option for teeth with irreversible pulpitis. However, the high frequency of inadequate canal obturations linked to apical periodontitis, despite new preparation and canal obturation technologies, increases the option to preserve the pulp vitality in current therapies.³ Indeed, improved understanding of the pulp biology and potential regenerative and healing of inflamed pulp has encouraged this therapeutic option in cases of irreversible pulpitis.

Considering the pulpo dentin complex healing potential when it is no longer irritating a high rate of successful treatment can be achieved. However, on teeth with irreversible pulpitis clinical signs and indicative symptoms, the inflamed part of the dental pulp must be removed by partial or full pulpotomy for the remaining pulp tissue to heal.⁴ This turns out to be a success when using bioactive endodontic cement, such as mineral trioxide aggregate (MTA), cement-enriched mixture (CEM), Biodentine... Thus, according to Glickman, full pulpotomy provides a greater chance to remove the irreversibly inflamed and infected pulp tissue.⁵ It consists of eliminating the whole pulp coronal up to canal orifices.

Several recent studies among young people and adults^{6,7} have shown very high success rates. Thus the objective of this study was to review the current endodontic literature so as to assess clinical and radiological criteria of pulpotomy therapy on mature permanent molars with irreversible acute pulpitis.

Materials and Methods

Search strategy: To find relevant articles on irreversible pulpitis care by pulpotomy, an electronic search strategy through databases of PubMed/MedLine via Hinari, Cochran Library and Science Direct was

used to search for the following keywords in various combinations by using "AND". Pulpotomy, permanent tooth, pulpitis.

A manual search was also undertaken from the list of found articles' references. Analyzing these references, unidentified articles from databases of different sources were selected. Only English or French language publications from January 2008 to April 2018 were used.

Databases

1. Medline: <http://www.ncbi.nlm.nih.gov/pubmed/>
2. Cochrane Library: <http://www.thecochranelibrary.com>
3. Science Direct: <http://www.sciencedirect.com>

Inclusion and non-inclusion criteria: Inclusion criteria for the above research were as follows: non-randomized or randomized clinical trials, sets and case reports, longitudinal studies, original articles. Non-inclusion criteria were in vivo studies on animals, comments, letters to the editor, histological studies, (it is not included because some parameters like sample

size, follow up, clinical controls and X-ray controls will not fit in the results table) and bibliographies reviews, systematic reviews.

Selecting articles: After reading titles and studies abstracts, potentially relevant articles were examined. Articles with a correct methodology were analyzed. In vivo studies on people with mature permanent teeth with irreversible pulpitis and having undergone a pulpotomy therapy were selected.

Hundred sixteen articles were found during the research process. After reading titles, 92 articles were excluded including 91 about immature permanent teeth and one about a systematic review. Twenty four articles were selected and eight of these were excluded because five have focused on teeth with no-irreversible pulpitis symptoms, one case was a chronic pulpitis and two were histological studies. Sixteen articles were eligible but full contents of seven articles were not available. Characteristics of each of the nine (9) analyzed articles are summarized in the diagram below (Fig. 1).

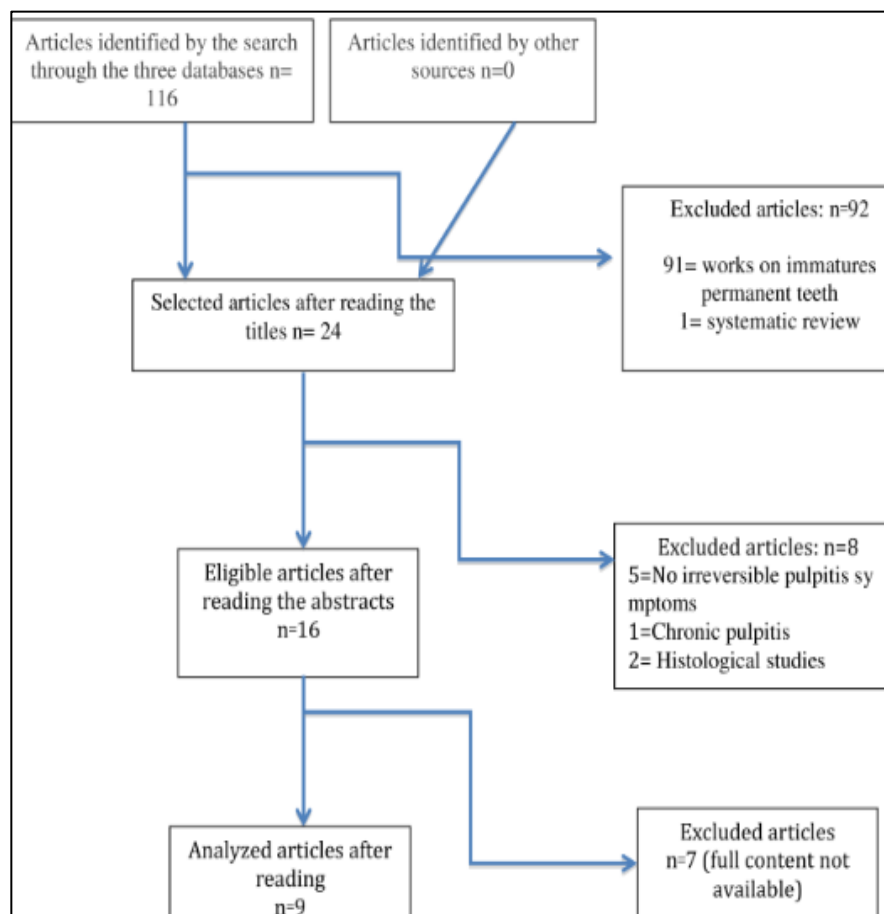


Fig. 1: Diagram of article selection

Results

Table 1

Author year	Journal	Type of study	Title	Sample size	Follow up	Materials	Clinical controls	X-ray controls	Conclusion
Taha NA 2018	International Endodontic Journal	Clinical trial	Outcome of full pulpotomy using Biodentine in adult patients with symptoms indicative of irreversible pulpitis	Sixty-four (64) permanent molar teeth	6 month et 1 year	Biodentine	On presentation to the clinic, 41% of the patients reported severe spontaneous pain scoring 10 (on a scale of 0–10) and the remainder had a history of severe lingering pain on cold drinks scoring 9–10 which was reproduced by cold testing. In the majority of cases (50 of 64, 78%), haemostasis was achieved within 4 min. Two days after pulpotomy, 93% of the cases reported complete relief of pain while the rest reported mild discomfort scoring 1–2. The success rate was generally high, with 98% clinical success at 1 year	The success rate was generally high, with 98% radiographic success at 1 year. Representative radiographs of the treated teeth are presented in Figs 2, 3 and 4. One tooth suffered a nonrestorable crown fracture at 3 months and was extracted; the tooth was otherwise asymptomatic and without radiographic signs of failure. Intraexaminer Cohen's kappa score ranged from 1.00 for outcome to 0.96 for radiographic signs of hard tissue barrier formation. Among cases with preoperative periapical rarefaction, seven of nine had complete healing: one case declined recall because of pregnancy, and one case remained unchanged (radiographic failure) and RCT was offered; however, the patient opted for further follow-up as the tooth was asymptomatic.	Biodentine was successful as a therapeutic material in full pulpotomy treatment of adult teeth with carious exposures. Clinical signs and symptoms indicative of partial irreversible pulpitis are not a contraindication and full pulpotomy might be considered as an alternative treatment approach to root canal treatment.
Taha NA 2017	International Endodontic Journal	Clinical trial	Assessment of Mineral Trioxide Aggregate pulpotomy in mature permanent teeth with carious exposures	Fifty-two (52) permanent molar teeth	3 years	MTA	Clinical signs and symptoms suggestive of irreversible pulpitis were established in 44/52 teeth, and periapical rarefaction was present in 14 teeth. Immediate failure occurred in one tooth. The recall	97.5% radiographic success during the first year, and 92.7% success at 3 years. All cases with periapical rarefaction were associated with improvement in the periapical index (PAI) score. Two cases	MTA full pulpotomy was a successful treatment option for cariously exposed pulps in mature permanent molar teeth.

							rate ranged from 92% at 3 months to 80.3% at 3 years, with an overall 100% clinical success	had new periapical rarefaction associated with dislodgment of the permanent restoration. A hard tissue barrier was detected radiographically in 5 cases and canal narrowing in 7 cases.	
Soni HK; 2016	Archive of Journal of Clinical and Diagnostic Research	A Case Report	Biodentine Pulpotomy in Mature Permanent Molar	One teeth (46)	3, 6, 12, 18 month	Biodentine	The tooth was fully functional and the patient was asymptomatic.	At six, twelve and eighteen months, follow-up of the tooth showed absence of any periapical pathology with normal periodontal ligament space.	In accordance to the favorable results of our cases, a reasonable argument supporting mature tooth pulpotomy in cases of irreversible pulpitis can be stated. Biomaterials such as Biodentine with pulp healing properties may challenge the complete philosophy of our conventional endodontic treatment. Case selection including age, status of pulp and control of bleeding; however, remains an important criterion for the same.
Kumar V; 2016	Contemporary Clinical Dentistry	A randomized controlled trial	Comparative evaluation of platelet-rich fibrin, mineral trioxide aggregate, and calcium hydroxide as pulpotomy agents in permanent molars with irreversible pulpitis: A randomized controlled trial	Sixty (60) individuals	6 et 12 month	Calcium Hydroxide (CH) Mineral Trioxide Aggregate (MTA) Platelet-Rich Fibrin (PRF)	There was a significant reduction in pain score from baseline to all test intervals ($P < 0.005$) in all groups A high clinical success rate of 93.75% was achieved at 7 days, which dropped to 85.4% at 12 months	No statistically significant difference was observed between radiographic outcomes of the three groups tested. Kappa value was 0.67 which indicated a substantial agreement between the two observers. A remarkable decline in radiographic success rate and hence the overall success rate was observed in all the groups at 6 month follow-up period. This rate dropped further at 12 month follow-up period. None of the teeth, however, had developed well-defined periapical pathology in this interval. present radiographs of sample	Pulpotomy as a treatment option for mandibular molars with irreversible pulpitis has an acceptable clinical success rate; however, long-term overall success rate remains questionable. There exists no significant difference between the success rates of CH, MTA, and PRF as pulpotomy agents in teeth with irreversible pulpitis

								case each from CH, MTA and PRF groups. The overall success rates (combined clinical and radiographic) of CH, MTA, and PRF groups at 1 year were 37.5%, 44.4%, and 35.7%, respectively	
Asgary S 2014	Clinical Oral Investigations	Clinical trial	Two-year results of vital pulp therapy in permanent molars with irreversible pulpitis: an ongoing multicenter randomized clinical trial	75 patients	27 month	Calcium enriched mixture	Mean follow-up times at 2 years were 24.61 ± 0.69 and 24.62 ± 0.72 months in RCT and VPT/CEM arms, respectively; a statistical difference was not observed. Treatment time spans were 94.07 min [coefficient of variation (CV)=29.01 %] and 31.09 min (CV=29.38 %) in the RCT and VPT/CEM, respectively ($P < 0.001$). Clinical success rates in the two study arms at 2-year follow-up were the same (98.19 %); outcomes in cases with preoperative periapical involvement were similar in the two study arms ($P = 0.117$)	The results of radiographic evaluation by the four examiners illustrated that overall consensus treatment outcome of radiographic evaluation between the study arms at 2 years did not show statistically significant difference	Two-year treatment outcomes of VPT/CEM are statistically non-inferior to one-visit RCT in human mature molar teeth with established irreversible pulpitis. However, in terms of cost-effectiveness, VPT/CEM significantly reduces expenditure compared with RCT. Outcomes of VPT/CEM were comparable at 6-month and 1- and 2-year follow-ups; therefore, it appears that 6-month recall is a reasonable time. Low-cost VPT/CEM is a predictable simple bio-regenerative method with an excellent prognosis; it can be considered an evidence-based alternative option to extraction and RCT.
Yazdani S; 2014	Iranian Endodontic Journal	multicenter randomized clinical trial	Health Technology Assessment of CEM Pulpotomy in Permanent Molars with Irreversible	385 subjects	6, 12 et 24 months	Calcium enriched mixture	Clinical success was based on the absence of signs and symptoms of inflammation/infection as well as tenderness to percussion. There was no significant difference between the two groups at 6-month, 1- and 2-year follow-	Compared to RCT, the new biotechnology, VPT/CEM, demonstrated greater success rates after one and two years (1-year: 92.2% vs. 70.3%, $P = 0.001$; 2-years: 86.7% vs. 79.5%, $P = 0.053$). As time passed the success rates	There was high-quality and long-term evidence from multicenter randomized clinical trials to support the use of VPT/CEM new biotechnology instead of RCT for patients suffering from irreversible pulpitis. Data relating to pain relief

			Pulpitis				<p>ups.</p> <p>Again VPT/CEM was assumed to significantly reduce post operative pain. In addition, the amount of painkillers taken after VPT/CEM was significantly less than the RCT group ($P>0.001$).</p>	<p>became more favorable in RCT group. While in CEM/VPT group the presence of preoperative radiographic periapical lesion did not significantly affect the success rate, in RCT group it did. The quality of treatment based on radiographic findings and in accordance to modified Strindberg Criteria was significantly different between the two groups ($P<0.001$) [27]; with 92.8% of VPT/CEM and only 66.3% of RCT cases having achieved good quality treatment. Moreover there was significant relationship between the quality of treatment and one-year post operative radiographic success rates</p> <p>This item was considered to be lower for VPT/CEM compared to RCT; as RCT usually requires working and postoperative radiographs. Not only VPT/CEM will reduce radiation dose for the patient and thus increases his/her safety, but also may significantly reduce treatment costs.</p>	<p>effect, radiographic outcomes, safety, costs, availability, accessibility and impact of VPT/CEM biotechnology, demonstrated superiority of VPT/CEM over RCT. We can conclude that VPT with a bio-regenerative material can be recommended for general clinical practice worldwide</p>
Yazdani S; 2013	Acta Odontologica Scandinavica	A multi-center randomized controlled trial	Treatment outcomes of pulpotomy in permanent molars with irreversible pulpitis using biomaterials	413 patients	7 day 12 month	Calcium enriched mixture (CEM) Mineral Trioxide Aggregate (MTA)	<p>sinus tract, redness and tenderness related to all treated teeth.</p> <p>Sixty-seven patients, 29 in the PMTA and 38 in the PCEM arms, did not attend due to lack of compliance or for personal reasons in the 12-month follow-up session. Overall there were 346 cases for primary outcome</p>	<p>Overall, the percentage of teeth with successful treatment (absence of symptoms, clinical/radiographic signs of pulpal/periapical disease) was 92 and 95% in PCEM and PMTA arms, respectively. All the failed cases were associated with a radiographic lesion.</p>	<p>There was no significant difference in the favorable outcomes of permanent molar teeth with irreversible pulpitis undergoing pulpotomy using CEM cement or MTA.</p>

							<p>analysis (long-term outcome); no significant difference was observed between clinical success rates of the two groups.</p> <p>Mean follow-up times were 12.90 ± 0.66 and 12.93 ± 0.69 months in the PCEM and PMTA groups, respectively; these were not significant ($p = 0.716$). At the 12-months follow-up, clinical examination revealed signs of periapical disease in 2.4% ($n = 4$) and 1.7% ($n = 3$) of the cases in PCEM and PMTA groups, respectively (Table III); no significant difference was found ($p > 0.05$).</p>		
Asgary S ; 2013	Clinical Oral Investigations	Clinical trial	One-year results of vital pulp therapy in permanent molars with irreversible pulpitis: an ongoing multicenter, randomized, non-inferiority clinical trial	407 patients	7 days, 6 and 12 month	CEM Calcium enriched mixture (BioniqueDent, Tehran, Iran)	<p>Clinical success in the two study arms at 6- and 12-month follow-up were "94.4 % and 91.3 %" and "98.3 % and 97.6 %" in RCT and VPT/CEM arms, respectively; there was no statistical difference ($P > 0.05$)</p>	<p>The radiographic intra-rater reliabilities were $\kappa 0.79$, $\kappa 0.85$, $\kappa 0.89$, and $\kappa 0.91$ for raters 1–4, respectively. The inter-rater reliabilities were raters 1/200.79, raters 1/300.88, raters 1/400.77, raters 2/300.89, raters 2/400.86, and raters 3/400.91. The results of radiographic evaluation by the four examiners after 6-month and 1-year follow-ups illustrated that the success rates between the two study arms was statistically different ($P 0.001$) (Table 2). Preoperative periapical involvement were present at baseline in 128 patients (31 %) in the two study arms [RCT ($n 065$) and VPT/CEM ($n 063$)]; no statistically significant</p>	<p>it is apparent that treatment outcomes of VPT/CEM is not only non-inferior but also may be superior to RCT in mature molars with irreversible pulpitis. Furthermore, our data suggests that VPT/CEM is a predictable procedure with an excellent intermediate- and long-term (6 and 12 months) prognosis and it may be considered a realistic alternative therapy to extraction/RCT. Moreover, the use of VPT/CEM in the treatment of irreversible pulpitis is highly</p>

								difference was observed (P00.779) [22]. Interestingly, in cases with preoperative periapical involvement, RCT produced more failures than VPT/CEM at the 6- and 12-month follow-ups (P00.001)	beneficial for patients as well as general dentists. The performance of biomaterials such as CEM cement in endodontics/dentistry may assist in the shift towards more biologic treatments
Barnkgel IH 2013	Iranian Endodontic Journal	Clinical trial	Pulpotomy of Symptomatic Permanent Teeth with Carious Exposure Using Mineral Trioxide Aggregate	11 teeth	24 to 42 months	Mineral Trioxide Aggregate	Clinical examination during the follow-up periods revealed that all patients were asymptomatic and free of clinical signs/symptoms including pain, swelling, presence of sinus tract, and tenderness to percussion	No changes in the periapical status of the treated teeth were evident on the all Follow-up periapical radiographies	In conclusion, pulpotomy using MTA could be a good alternative for RCT for managing symptomatic mature permanent teeth with carious exposure. Since samples treated in this study were limited in number, large-scale multicenter clinical trials are highly encouraged.

Discussion

In dentistry it is universally accepted that the vital pulp tissue should be preserved if possible. However, clinicians are reluctant to carry out conservative treatment of the pulp vitality once the irreversible pulpitis diagnosis is made. This clinical diagnosis of irreversible pulpitis is mainly based on tests and clinical symptoms. Indeed, no consistent relationship between clinical symptoms and histopathological pulp status has been established.⁸ There is no clear evidence to substantiate the boundary between the reversible pulpitis and the irreversible pulpitis. A recent systematic review has reported "an insufficient correlation between the pain intensity of thermal/cold stimulus of a tooth with irreversible pulpitis and the pulp pathology".⁹ Furthermore, there are reports of successfully preserved pulp vitality of teeth with signs/symptoms of irreversible pulpitis and ligament thickening,¹⁰ which highlights the dental pulp high-capacity as a soft tissue to heal. Thus we conducted this literature review aiming to assess the clinical and radiographic pulpotomy criteria on mature permanent molars with irreversible pulpitis. Results of this study suggested positive success rates for this therapy. Indeed, available studies showed that the assessment is generally made after the treatment, on the seventh day at three, six, 12, 24 and 36 months. Results of all these studies are analyzed according to the patient age, time control, postoperative pain, type of capping materials used, clinical success (absence of abscess, swelling and tooth functional impotence) radiographic success with no increase of ligament thickening and periapical lesion.^{11,12}

Regarding the patient age, available studies have shown that it is not a risk factor for this therapy. Indeed, six studies of this review have included patients of up to 69 years old and reported high rates of success of the full pulpotomy suggesting that age has no effect on the pulpotomy result.^{13,15} But, according to Alqaderi et al. only the young dental pulp is able to heal by pulpotomy therapy because it is softer and has better healing and regenerating potential after removal of the infected pulp tissue.¹⁶

Regarding the postoperative pain, some studies.^{7,15} have assessed it from the first to the seventh day of treatment. According to Taha et al in 2017 on a sampling of 52 patients, the postoperative pain had gone except for a woman who received a root canal treatment. Five patients had difficulty chewing and one patient reported analgesic.⁷ intake. A study of Taha et al. in 2018 on 64 patients showed that 41% of patients reported severe spontaneous pain scoring ten on a pain scale, and the rest had severe persistent pain caused by cold drinks scoring nine to ten.⁶ Two days after pulpotomy, 93.8% of cases reported a complete pain relief while the remaining reported light difficulty chewing.⁶ According to Barnkgkei et al study.¹⁸ on 12

mature permanent molars with irreversible pulpitis, no clinical complaints of discomfort or sensitivity after 24 hours have been reported. This postoperative pain or chewing discomfort during the week of the treatment could be explained by the extent of the pulp inflammation that is impossible to clinically diagnose.

Asgary and Eghbalclinical trial in 2010.¹⁹ involving more than 400 participants showed that pulpotomy treatment with CEM or MTA was just as effective for pain relief and had a clinical and radiographic high rate success after one year.

These pains in cases of irreversible pulpitis are due to an increase in blood volume in the inner pulp portion made of dental walls. The pulpotomy reduces the blood volume of this inflamed pulp which can provide relief to the patient.¹

In a randomized clinical trial on postoperative pain and comparing pulpotomy and pulpectomy in one visit, it was noted that effects of the pain relief during a pulpotomy were significantly higher than during pulpectomy.¹⁹ this could be explained in part by the risk of overused obturation products or over instrumentation during pulpectomy.

Regarding the material used, all published results on the subject at three six 12, 18, 24 and even 36 months were satisfactory whether it is with Biodentine, MTA, CEM, CH or Platelet-Rich FibrinPRF. Taha et al. 2017states that at six months, 63 out of 64 patients were recalled with 98.4% of clinical and radiographic success. At one year 59 out of 63 have been recalled with 100% clinical success and 98.4% radiographic success with Biodentine use. Radiologically, seven out of eight recalled cases with periapical rarefaction have improved their periapical index (PAI) score. Healed periapical has been detected radiographically in four cases. Additionally, he reports 100% clinical success rate with MTA and 97.5% radiographic success in the first year and 92.7% after three years.⁷

According to Asgary, the clinical success of pulpotomy with CEM was 98.19% over a period of 27 months. However, the radiographic success rate was 86.7%.¹²

Kumar V. et al. 2016 reported 37.5% 44.4% and 35.7% clinical and radiological success rate over one year respectively with CH, MTA and PRF use.²⁰ This study of Kumar V. has reported no statistically significant difference ($P = 0.550$) between clinical and radiographic findings in all three groups. Asgary et al. study comparing the CEM and the MTA, showed that clinical and radiographic success rate after 12 months follow up, were 98 and 95% for MTA and 97 and 92% for CEM. There is no significant difference in clinical success rates ($p = 0.7$) and radiographic success rates ($p = 0.4$) between the two groups.¹⁴ Different materials used did not affect the pulpotomy success rate. It was suggested that the failure to preserve the pulp vitality by pulpotomy on mature permanent teeth with

irreversible acute pulpitis may be related to bacterial infiltration of the remaining vital pulp in canals through a defective restoration.²¹

Recent studies have reported that the most important contributing factor to a successful treatment is a maximum and very tight sealing of the remaining dental pulp using a proper final coronary restorative material to prevent bacterial leakage.^{16,17} Furthermore, the effect of pulp capping materials, type of permanent coronary restorative materials and the X-ray periapical state of treated teeth on the success rate was assessed using a meta-regression analysis. Two studies had used teeth with periapical.^{12,22} while others.^{23,24} had used teeth without radiographic periapical lesions. The three variables are not significantly related to success rates. Typically, differences in success rates between different capping materials, coronary restoration materials or between different periapical states were limited. However, studies have shown that MTA products as capping materials provide better clinical results than CH, traditionally used to protect exposed pulp.²⁵ Chugal et al. 2001 reveals that the main biological influencing factor of treatment results is the presence of preoperative ligament thickening.²⁶

According to Asgary et al. 2014 the success rate of the pulpotomy on vital teeth with irreversible acute pulpitis with ligament thickening was considerably lower compared to the vital teeth with an abnormal periodontal ligament. However, CEM groups showed a better trend of success during the two years follow-up.¹² Based on this review's results, the type of permanent restoration as compared to the pulp capping materials was not related to the pulpotomy success rate.²⁷ However, a Kunert et al. 2015 have reported that a prosthetic coronary restoration showed the highest success rate after the pulpotomy followed by amalgam and finally restoration with composite.²³

In this review, clinical success rates are higher than radiographic success rates which decrease with long-term follow up. Indeed Taha et al. reported in 2017 100% clinical success and 97.5% radiographic success in the first year follow up and 92.7% of radiograph success after three years follow up.⁷ Asgary et al. in 2013, had reported a 97% clinical success rate against 92% radiographic success rate.¹⁴ When the radiographic success rate is included in the clinical success rate, the overall success rate is much lower. This is the case of the study by Kumar V. et al. which showed 37.5%, 44.4% and 35.7% success rates comparing three types of capping materials.²⁰ Since the clinical success rate is much higher than the radiographic's we can assume that the pulpotomy treatment failure is mainly due to asymptomatic apical periodontitis. Varun results corroborate those of Mc Dougal et al. study.²⁸ which reported 90% clinical success rate at six months and 78% at 12 months. The radiographic success however, was only 49% at six months and 42% at 12 months on

painless teeth. Two common causes are usually attributed to a decrease in the success rate overtime which are bacterial percolation to the coronal and a residual infection. A long-term perfect coronal sealing is difficult to get with current restorative materials available to us hence the necessity for prosthetic crowns after pulpotomy.

The pulp pretreatment state is also a key factor in determining this technique success rate. Although the bleeding control capacity is usually used as an indicator to assess the extent of the inflammation of the pulp, it cannot, however, be precisely correlated to the extent of the inflammation in all cases.²⁹ Thus, many cases of pulp inflammation at advanced stages may be included in a study and could affect the results. The availability of potential better diagnosis techniques can better help in selecting cases and thus increase the success rate of this technique.

In this review, studies have compared the pulpectomy to the pulpotomy and we found that clinical results are similar in the short term as well as the long-term, but there is a difference in radiographic success rates for pulpotomy. Indeed, Yazdani et al. in 2014 reports that there is no difference in clinical success rate between groups of pulpotomy and pulpectomy at six months, one year and two years. However, there was a difference in radiographic success rates at one year with 92.2% for pulpotomy and 70.3% for pulpectomy and two years with respectively 86.7% and 79.5%. The difference was statistically significant with $P = 0.001$.²¹ Asgary et al. in 2014, reported that clinical success rates in two study groups were similar (98.19%) and that there was no difference $p = 0.053$. He reported that the average treatment time was about three times greater in the pulpectomy group than in the pulpotomy's/CEM: 94.07 against 31.09 min $P < 0.001$.¹²

Asgary et al. in 2013, reported a pulpectomy success rate of 94.4% at six months and 91.3% at twelve months compared with 98.3% success rate at six months and 97.6% at twelve months for pulpotomy. The radiographic success rate was significantly higher in the pulpotomy group than in the pulpectomy's during follow up.¹⁴

Indeed, living with mature permanent molars with irreversible pulpitis' gold standard treatment being the pulpectomy, to replace it with the new treatment, the latter should provide higher success or at least equal to that of the treatment reference with few extras benefits.³⁰ Thus according to Asgary et al. in 2014 reduced time and cost are the benefits of pulpotomy. Furthermore, there's less destruction of dental tissue, fewer side effects, easy to apply and more security (preserving the vitality, increasing survival rate, reducing the pain) and less -exposure to X-rays. He has demonstrated that pulpotomy was statistically not inferior to pulpectomy considering their radiographic success after six months and one year follow up.¹²

Another study had revealed that overall success rates at six months to three years were almost unchanged.⁷ Therefore it seems that three to six months follow up is a reasonable time to assess pulpotomy results. However, in Yazdani et al. works the healing probability of cases has increased during a two years period time for the pulpectomy; he found 70.3% at one year and 79.5% at two years.²¹ This is consistent with Orstavik's works which had demonstrated pulpectomy increasing success rate overtime.³¹ The pulp healing potential known as "irremediable" as well as the biocompatibility of pulp capping materials could explain this difference in success rates in these different time intervals.^{27,32} A pulp at an irreversible pulpitis state contains stem cells (DPSCs IPs) with huge regenerating potential.³³ DPSCs IPs will allow the pulp to heal after an appropriate treatment.^{34,35} Furthermore, biomaterials can play an essential role in regenerative endodontics and their success in Endodontics can entirely change the philosophy of Endodontic treatment.

Conclusion

The review of this literature has shown that full coronary pulpotomy on mature permanent molars with irreversible acute pulpitis can have a 98% success rate. This treatment is considered to be successful when there are no symptoms and clinical signs such as pain, swelling, abscess and no radiological signs such as the increase of the pulp chamber or the appearance of a periapical lesion.

Multicentered randomized clinical studies have demonstrated this treatment quality and durability compared to the pulpectomy. Results have shown a full sedation of pain 48H after treatment with 93.8% rate. The success rate, clinically as well as radiographically, at six months was the same at one and three years.

References

1. Keenan JV, Farman AG, Fedorowicz Z. Antibiotic use for irreversible pulpitis. *The Cochrane Database of Systematic Reviews*. 2005;2.
2. Seltzer S, Bender IB, Ziontz M. The dynamics of pulp inflammation: correlations between diagnostic data and actual histologic findings in the pulp. *Oral Surg Oral Med and Oral Pathology*. 1963;16:969-77.
3. Van der Veken D, Curvers F, Fieuws S. Prevalence of apical periodontitis and root filled teeth in a belgian subpopulation found on CBCT images. *Int Endod J*. 2017;50(4):317-29.
4. Ricucci D, Loghin S, Siqueira JF. Correlation between clinical and histologic pulp diagnoses. *J of Endod*. 2014;40(12):1932-39.
5. Glickman GN. AAE consensus conference on diagnostic terminology: background and perspectives. *J of Endod*. 2009;35(12):1619-20.
6. Taha NA, Abdelkader SZ. Outcome of full pulpotomy using biodentine in adult patients with symptoms indicative of irreversible pulpitis. *Int Endod J*. 2018;51(8):819-28.
7. Taha NA, Ahmad MB, Ghanim A. Assessment of mineral trioxide aggregate pulpotomy in mature permanent teeth with carious exposures. *Int Endod J*. 2017;50(2):117-25.
8. Yassen GH, Platt JA. The effect of nonsetting calcium hydroxide on root fracture and mechanical properties of radicular dentine: a systematic review. *Int Endod J*. 2013;46(2):112-18.
9. Jafarzadeh H, Rosenberg PA. Pulse oximetry : review of a potential aid in endodontic diagnosis. *J of Endod*. 2009;35(3):329-33.
10. Mohammadi Z, Dummer PMH. Properties and applications of calcium hydroxide in endodontics and dental traumatology. *Int Endod J*. 2011;44(8):697-30.
11. Alqaderi H, Lee CT, Borzangy S. Coronal pulpotomy for cariously exposed permanent posterior teeth with closed apices: a systematic review and meta-analysis. *J of Dent*. 2016;44:1-7.
12. Asgary S, Eghbal MJ, Ghoddusi J. Two-year results of vital pulp therapy in permanent molars with irreversible pulpitis: an ongoing multicenter randomized clinical trial. *Clin Oral Investigations*. 2014;18(2):635-41.
13. Barnkgkei IH, Halboub ES, Alboni RS. Pulpotomy of symptomatic permanent teeth with carious exposure using mineral trioxide aggregate. *Iran Endod J*. 2013;8(2):65-68.
14. Asgary S, Eghbal MJ, Ghoddusi J et al. One-year results of vital pulp therapy in permanent molars with irreversible pulpitis: an ongoing multicenter, randomized, non-inferiority clinical trial. *Clin Oral Investigations*. 2013;17(2):431-39.
15. Taha NA, Mohammad AK. Partial pulpotomy in mature permanent teeth with clinical signs indicative of irreversible pulpitis: a randomized clinical trial. *J of Endod*. 2017;43(9):1417-21.
16. Alqaderi H, Al-Mutawa SA, Qudeimat MA. MTA pulpotomy as an alternative to root canal treatment in children's permanent teeth in a dental public health setting. *J of Dent*. 2014;42(11):1390-95.
17. Taha NA, Mohammad AK. Partial pulpotomy in mature permanent teeth with clinical signs indicative of irreversible pulpitis: a randomized clinical trial. *J of Endod*. 2017;43(9):1417-21.
18. Barnkgkei IH, Halboub ES, Alboni RS. Pulpotomy of symptomatic permanent teeth with carious exposure using mineral trioxide aggregate. *Iran Endod J*. 2013;8(2):65-8.
19. Asgary S, Eghbal MJ. The effect of pulpotomy using a calcium-enriched mixture cement versus one-visit root canal therapy on postoperative pain relief in irreversible pulpitis: a randomized *clin trial Odontology*. 2010;98(2):126-33.
20. Kumar V, Juneja R, Duhan J. Comparative evaluation of platelet-rich fibrin, mineral trioxide aggregate, and calcium hydroxide as pulpotomy agents in permanent molars with irreversible pulpitis: a randomized controlled trial. *Contemp Clin Dent*. 2016;7(4):512-18.
21. Yazdani S, Mohammad-Pooyan J, Bahareh T. Health technology assessment of CRM pulpotomy in permanent molars with irreversible pulpitis. *Iran Endod J*. 2014;9(1):23-9.
22. DeRosa TA. A retrospective evaluation of pulpotomy as an alternative to extraction. *Gen Dent* 2006;54(1):37-40.
23. Kunert GG, Kunert IR, Da Costa Filho LC. Permanent teeth pulpotomy survival analysis: retrospective follow-up. *J of Dent*. 2015;43(9):1125-31.

24. Simon S, Perard M, Zanini M. Should pulp chamber pulpotomy be seen as a permanent treatment? Some preliminary thoughts. *Int Endod J*. 2012;46(1):79-87.
25. Qudeimat MA, Alyahya A, Hasan AA. Mineral trioxide aggregate pulpotomy for permanent molars with clinical signs indicative of irreversible pulpitis: a preliminary study. *Int Endod J*. 2017;50(2):126-34.
26. Chugal NM, Clive JM, Spångberg LS. A prognostic model for assessment of the outcome of endodontic treatment: effect of biologic and diagnostic variables. *Oral Surg, Oral Medicine, Oral Pathology, Oral Radiology, and Endod*. 2001;91(3):342-52.
27. Asgary S, Eghbal M J. Treatment outcomes of pulpotomy in permanent molars with irreversible pulpitis using biomaterials: a multi-center randomized controlled trial. *Acta odontol scand*. 2013;71(1):130-36.
28. McDougal RA, Delano EO, Caplan D. Success of an alternative for interim management of irreversible pulpitis. *J of the Am Dent Association*. 2004;135(12):1707-12.
29. Ward J. Vital pulp therapy in cariously exposed permanent teeth and its limitations. *Aust Endod J* 2010;28(1):29-37.
30. Piaggio G, Elbourne DR, Altman DG. Reporting of noninferiority and equivalence randomized trials: an extension of the consort statement. *J of the Am Med Association*. 2006;295(10):1152-60.
31. Orstavik D. Time-course and risk analyses of the development and healing of chronic apical periodontitis in man. *Int Endod J*. 1996;29(3):150-55.
32. Asgary S, Moosavi SH, Yadegari Z. Cytotoxic effect of mta and CRM cement in human gingival fibroblast cells. scanning electronic microscope evaluation. *The New York State Dent J*. 2012;78(2):51-54.
33. Wang Z, Jian P, John T. Putative stem cells in human dental pulp with irreversible pulpitis: an exploratory study. *J of Endod*. 2010;36(5):820-25.
34. Asgary S. Calcium-enriched mixture pulpotomy of a human permanent molar with irreversible pulpitis and condensing apical periodontitis. *J of Conserv Dent*. 2011;14(1):90.
35. Asgary S, Eghbal MJ, Fazlyab M. Five-year results of vital pulp therapy in permanent molars with irreversible pulpitis: a non-inferiority multicenter randomized clinical trial. *Clin Oral Investigations*. 2015;19(2):335-41.