

## Non-syndromic bilateral mandibular supernumerary premolars: A case report with CBCT

Harsh Misra<sup>1,\*</sup>, Lalit C. Boruah<sup>2</sup>, B. Rajkumar<sup>3</sup>, Juhin H. Patel<sup>4</sup>, Ajinkya M. Kadam<sup>5</sup>

<sup>1,5</sup>M.D.S, <sup>2,3</sup>Professor, <sup>4</sup>B.D.S, <sup>1-3</sup>Babu Banarasi Das College of Dental Science, University, Lucknow, Uttar Pradesh, <sup>4,5</sup>Bharti Vidyapeeth Deemed University Dental College and Hospital, Pune, Maharashtra, India

**\*Corresponding Author:**

Email: dr.harsh.mishra@gmail.com

### Abstract

Multiple supernumerary teeth are rare in patients without any associated conditions, and the mechanisms responsible for the development of multiple supernumerary teeth in such patients remain unclear. The present case involved a 25-year-old boy with additional bilateral four supernumerary mandibular premolars which is not very common finding in routine practice.

**Keywords:** Developmental abnormality, Multiple supernumerary teeth.

### Introduction

Supernumerary teeth are teeth that form in addition to the normal dental formula. There is possibility of single or multiple supernumerary teeth and also they can occur unilaterally or bilaterally and can arise in the maxilla, mandible and/or both. The prevalence of occurrence of such teeth in males is twice that of females. Although the occurrence of one or two supernumerary teeth is common (76–86% cases involve one super-numerary tooth; 12–23% cases involve two supernumerary teeth), cases involving greater numbers of supernumerary teeth are rare ( $\geq 3$  teeth develop in 2–8% cases).<sup>1</sup>

The etiology of supernumerary teeth remains unclear and various theories have been postulated in previous reports. In particular many syndromes such as cleft lip and palate cleidocranial dysplasia (CCD), familial adenomatous polyposis or Gardner's syndrome and developmental conditions found to be associated with tooth development.<sup>1</sup>

### Case Report

A 25-year-old boy was referred to our hospital for the treatment of multiple impacted supernumerary teeth, which were detected on a dental panoramic radiograph. Patient has undergone endodontic treatment for one of the tooth and wanted a prosthetic crown for the same. On asking about his chief complaint it was found that a supernumerary tooth was placed lingually which was hindering his mastication. A panoramic radiograph revealed multiple supernumerary teeth. In the mandible, there were four supernumerary teeth one behind each right and left first premolar and the other two behind both second premolars. Computed tomography (CT) con-firmed that all of the impacted supernumerary teeth were located on the palatal or lingual side of the premolars and were similar in size and had normal premolar crown shapes. Medical examinations done has ruled out Nance–Horan

syndrome, trichorhinophalangeal syndrome familial adenomatous polyposis robinow syndrome hallermann–streiff syndrome CCD, rothmund–thomson syndrome, and oro-faciodigital syndrome I which are associated with super-numeracy teeth.

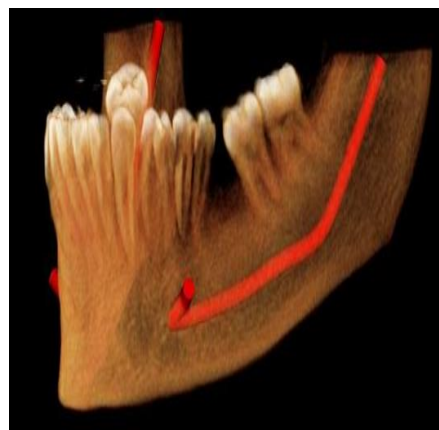


Fig. 1

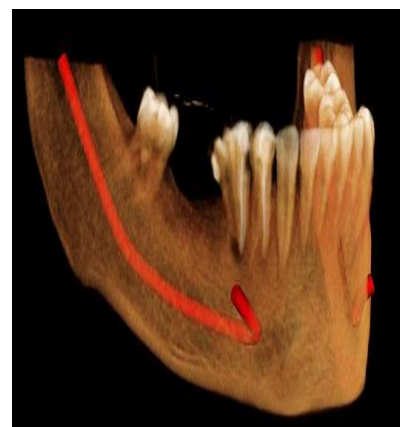

Fig. 2

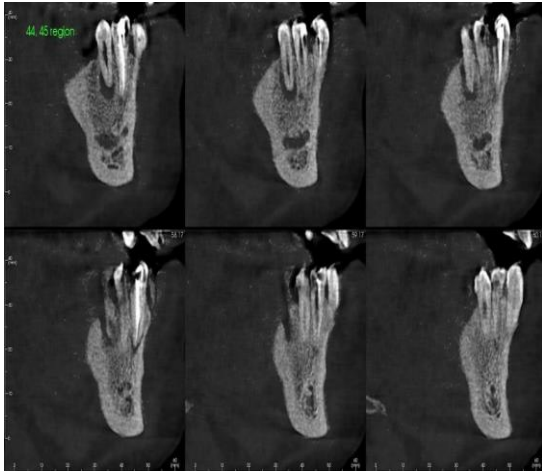


Fig. 3

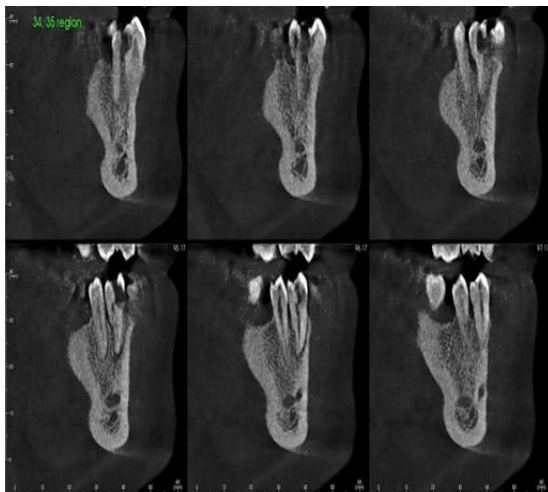


Fig. 4

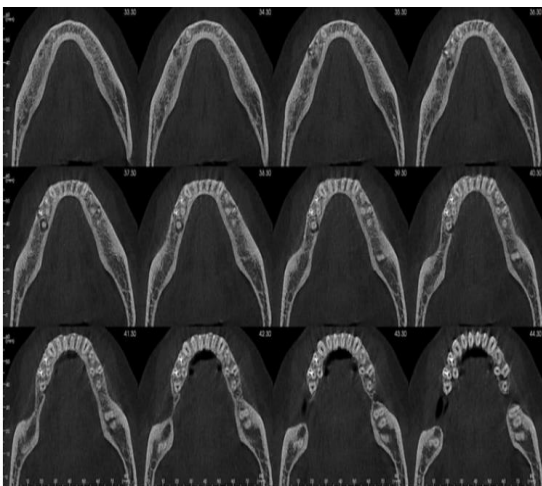


Fig. 5

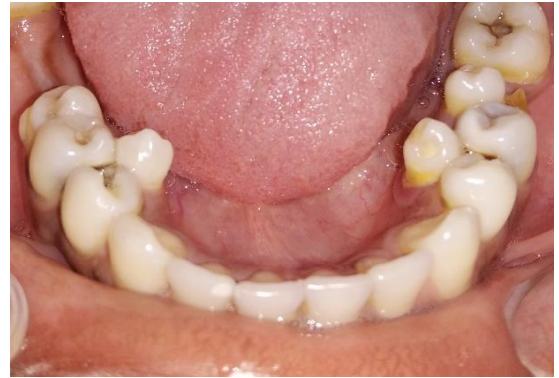

Fig. 6

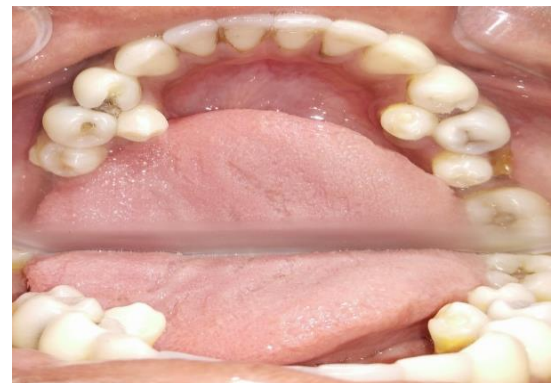


Fig. 7

**Discussion**

The aetiology of supernumerary teeth remains unclear but various theories have been proposed, including the atavism (evo-lutionary throwback) or phylogenetic theory the tooth germ dichotomy theory and the dental lamina hyperactivity theory. In addition, it has been suggested that genetic and environmental factors might also play a role in the development of supernumerary teeth.<sup>2-4</sup> According to the dental lamina hyperactivity theory a supplemental form of tooth can arise via the lingual extension of an additional tooth bud, and a rudimentary form of tooth can develop via the proliferation of epithelial remnants of the dental lamina.<sup>5,6</sup> Furthermore, the Rose theory suggests that if the dental lamina is not reabsorbed it continues to proliferate and produces new normally shaped buds of the aforementioned theories, the dental lamina hyperactivity theory has attracted the most support in the literature.<sup>2</sup>

We analysed these kinds of cases focusing on the locations (lingual or palatal side of permanent teeth) and distribution patterns of the supernumerary teeth (regular or irregular) and the extent of their calcification and development, and classified them into three figures. (Fig. 1) all supernumerary teeth are located on the lingual or palatal side, are arranged in a regular manner and exhibit similar degrees of calcification and development. (Fig. 2) the supernumerary teeth are arranged in an irregular pattern and exhibit varying

degrees of calcification and development. (Fig. 3) the teeth demonstrate a mixture of Fig. 1,2 features.<sup>7</sup>

### References

1. Report Two non-syndromic cases of multiple supernumerary teeth with different characteristics and a review of the literature Katsu Takahashia, Yumiko Togo\*, Kazuyuki Saitoa, Honoka Kisoa, Boyen Huangb, Hiroko Tsukamotoa, Kazuma Fujimuraa, Kazuhisa Besshoa. *J of Oral and Maxillofac Surg, Med, and Pathol* 2016.
2. Rajab LD, Hamdan MA. Supernumerary teeth: review of the literature and asurvey of 152 cases. *Int J Paediatr Dent* 2002;12:244–54.
3. De Oliveira Gomes C, Drummond SN, Jham BC, Abdo EN, Mesquita RA. A survey of 460 supernumerary teeth in Brazilian children and adolescents. *Int J Paediatr Dent* 2008;18:98–106
4. Diaz A, Orozco J, Fonseca M. Multiple hyperodontia: report of a case with 17supernumerary teeth with non syndromic association. *Med Oral Patol Oral Cir Bucal* 2009;14:229–31
5. Wang XP, Fan J. Molecular genetics of supernumerary tooth formation. *Genesis* 2011;49:261–77.
6. Galluccio G, Castellano M, La Monaca C. Genetic basis of non-syndromicanoma-lies of human tooth number. *Arch Oral Biol* 2012;57:918–30.
7. Report A rare case of metachronous multiple supernumerary teeth in the bilateral premolar region of the mandible. Kan-ichi Kogaa, Ryoji Yoshidaa, Takuya Nakamuraa, Yuichiro Matsuokaa, Hisashi Takeshitaa, Nozomu Takahashia, Masafumi Nakamotoa, Akimitsu Hirakib, Masanori Shinoharac, Hideki Nakayamaa