

## Radix Entomolaris: Case reports

Anjana Banthia Nahar

<sup>1</sup>Resident, Rishiraj College of Dental Science, Bhopal, Madhya Pradesh, India

**\*Corresponding Author: Anjana Banthia Nahar**

Email: [dranjananahar@gmail.com](mailto:dranjananahar@gmail.com)

### Abstract

**Introduction:** The goals of root canal treatment are thorough cleaning and shaping of root canal system for elimination of microbes and prepare the canal system for receiving the inert materials. For achieving this goals a thorough knowledge of root canal system anatomy should be occurs, all the canal should be located and proper cleaning should be done, but some tooth have different anatomy which causes increase the failure rates of root canal treatments like radix entomolaris and radix paramolaris.

This paper highlighted the case series of radix entomolaris, a developmental variations occurring on mandibular molars which is associated with extra root and extra canal in unusual position. This extra root may be present on lingual side and canal should be located between the mesiolingual to distal canal these called redix entomolaris, other variant is called radix paramolaris in which extra root present on buccal side and canal located between mesio buccal canal to distal canal. Hence it is mandatory to take preoperative radiographs [take radiographs in mesial and distal angulations] and minute inspection of dentinal maps is necessary.

**Keywords:** Radix entomolaris, Radix paramolaris, Irreversible pulpitis, Periapical radiolucency.

### Case Reports

#### Case 1

A 20 year female patient reported with pain in lower right back tooth region since 6 days. Pain was intermittent type, aggravated on taking cold foods and persist even after the removal of stimulus. A radiograph was taken with different angled which show restoration closed to pulp and peri apical radiolucency and an additional root.

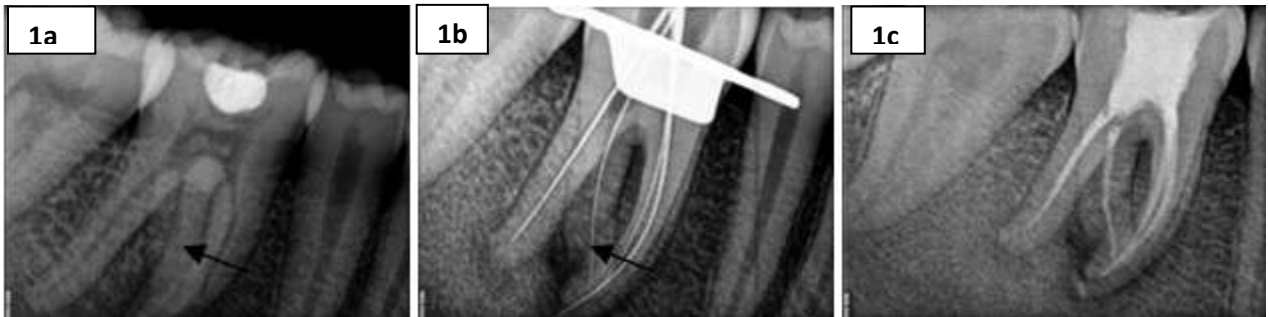
Local anesthesia was administered and the tooth was isolated under rubber dam. Access bur no: 1 [denstply Switzerland]. The first distal canal has been found slightly away from the centre[buccaly], and indicating that the other canal may be on disto-lingual side. For this canal access cavity was slightly modified from triangular to trapezoidal from and the 4<sup>th</sup> canal was located. The DG -16 explorer was used for location of orifice of canals and patency of canal checked with 10 number K-file [Mani Japan]. Working length was determine by electronic apex locator root ZX mini [j morita] and conformed by radiographically. A thorough cleaning was done by hypo 5% and shaping was done by Hyflex CM rotatry file system up to 4% 30 number crown down technique. Glyde EDTA gel [denstply] used as lubricant. 20ml of irrigants used for each canal for irrigation. Obturation was performed with cold lateral condensation technique. Access cavity was restore with Tetric N – ceram Bulk Fill with self etch bond [Ivoclar]. Patient recall after 3 months no sign of pain was present and radiographs was taken which had showed no periapical pathology [Fig. 1]

#### Case 2

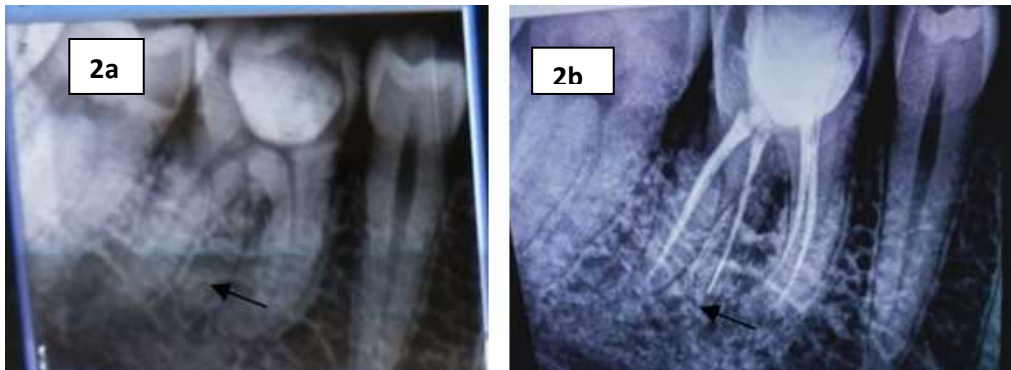
A 25 year old female patient came with toothache in lower right back tooth region. Pain was of continuous type and with occurred during night. preoperative radiographs was

taken with different angle shows restoration close to pulp and extra root with no periapical pathology. Pulp vitality was done with cold test shows irreversible pulpitis with lower right first molar.

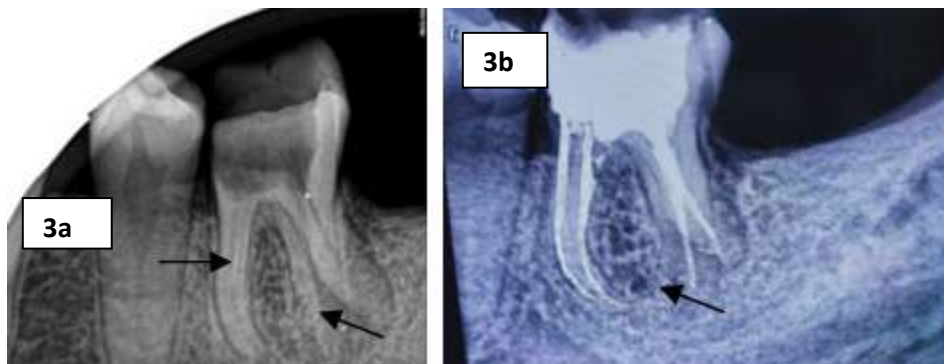
Local anesthesia was administered and the tooth was isolated under rubber dam. Pre endodontic build up done with distoligual wall. Access bur no:1 [denstply Switzerland]. The first distal canal has been found slightly away from the centre [buccaly], and indicating that the other canal may be on disto-lingual side. For this canal access cavity was slightly modified from triangular to trapezoidal from and the 4<sup>th</sup> canal was located. The DG -16 explorer was used for location of orifice of canals and patency of canal checked with 10 number K-file [Mani Japan]. Working length was determine by electronic apex locator root ZX mini [j morita] and conformed by radiographically. A thorough cleaning was done by hypo 5% and shaping was done by Hyflex CM rotatry file system up to 4% 30 number crown down technique. Glyde EDTA gel [denstply] used as lubricant. 20ml of irrigants used for each canal for irrigation. Obturation was performed with cold lateral condensation technique. Access cavity was restore with Tetric N – ceram Bulk Fill with self etch bond. Patient recall after 3 months no sign of pain was present and radiographs was taken which had showed no periapical pathology.[fig. 2]



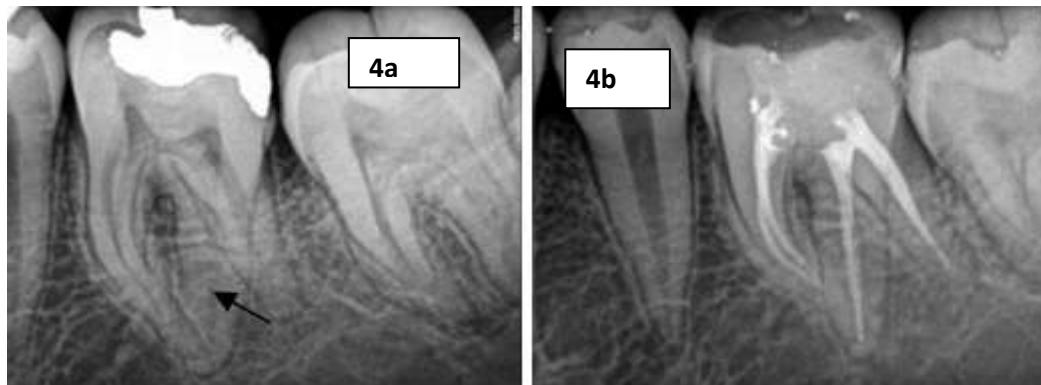
**Fig. 1:** Radiographs shows restoration close to pulp and extra root and periapical pathology. 1b working length,1c 3 month follow heal periapical pathology.



**Fig. 2:** Radiographs shows restoration close to pulp and extra root. 2b -3 month follow up heal periapical pathology



**Fig. 3:** Radiographs shows separated instrument and extra root. 3b -3 month follow up



**Fig. 4:** Radiographs shows secondary caries close to pulp and extra root. 4b -3 month follow up

**Case 3**

A 28 years female came to department with chief complain of fractured restoration in lower left back tooth region since 6 days. Patient had no pain and negative pain on percussion test. Preoperative radiographs was taken shows incomplete root canal treatment with separated instruments in mesiobuccal canal and extra root with no peri apical pathology. LA administered and rubber dam applied removal of old restoration was done and location of orifices of canal was by DG 16 explorer. The 4<sup>th</sup> canal orifice was locate between mesiolingual orifice to distal orifice. separated instrument bypass and cleaning, shaping, obturation done.

**Case 4**

A 20 years male came to department with chief complain of fractured restoration in lower left back tooth region since 6 days. Patient had pain and positive pain on percussion test. Preoperative radiographs shows restore left first mandibular molar and extra root with periapical pathology. LA administered and rubber dam applied removal of old restoration was done and location of orifices of canal by DG 16 explorer. The 4<sup>th</sup> canal orifice was locate between mesiolingual orifice to distal orifice. canals. cleaning shaping done and obturation done with cold lateral condensation.

**Discussion****Prevalence of Radix Entomolaris and Paramolaris**

The endodontist must have comprehensive knowledge about root canal morphology. Different type's of root curve and other anatomical changes could be present in teeth subjected to endodontic treatment. If a root canal system is not located, this may reduce the chance of treatment success.<sup>1</sup>

Mandibular molars, mainly first molars, may have an additional root located lingual or buccal. Although this a rare occurrence in white populations it is more common in Asian populations<sup>2</sup>Table 1.

**Table 1:** Percentage of occurrence of radix in different populations

Populations	Percentage
African populations	3%
Eurasian and Indian	Less than 5%
The Chines, Eskimo and American Indians	5% to 30%
Caucasian	3.4% to 4.2%

**Table 2:** Percentage of occurrence of radix in different molars

1 <sup>st</sup> Molar	2 <sup>nd</sup> Molar	3 <sup>rd</sup> Molar
0%	.5%	2%

**Table 3:** De Moor classification , based on the curvature

<b>Type I</b>	Straight- lingual orientation,
<b>Type II</b>	initially curved entrance which continues as a straight root/root canal.
<b>Type III</b>	to an initial curve in the coronal third of the root canal and a second curve beginning in the middle and continuing to the apical third.

A radix entomolaris can be found on the 1<sup>st</sup>, 2<sup>nd</sup> and 3<sup>rd</sup> mandibular molar, minimal frequently on the second molar. radix entomolaris from 50% to 67% i a bilateral occurrence.

Bolk reported the occurrence of a buccally located addition root: radix paramolaris. This macrostructure is very rare and occurs less frequently than Radix entomolaris. Table 2.

**Morphology of the Radix Entomolaris and Paramolaris**

The radix entomolaris [RE] is a supernumerary root located distolingually in mandibular molars, whereas the radix paramolaris is an extra root located mesiobuccal, usually contains a single root canal. The orifice of radix entomolaris is located distal to mesiolingually from the main canal or canals of distal root: the orifice of the Radix paramolaris is located mesio-to distobuccally from the main root canal on the pulp chamber floor leads to these orifices.<sup>4</sup>In a study on Burmese subjects, about 10.1% of observed teeth had an extra distal root on lingual aspect [radix entomolaris].<sup>3</sup> It is easy to assume that the canals curve only to the mesial or the distal, but because these roots have developmental variation they also have a curvature in the buccolingual dimension that cannot be assessed radiographically.<sup>5</sup> according to the classification of De Moor et al, based on the curvature of the separate entomolaris variants in bucco-lingual orientation, 3 types can be identified. Table 3

A classification by Carlsen and Alexandersen describes four different types of radix entomolaris according to the location of the cervical part of entomolaris. Table 4

The paramolaris is located [mesio]buccally. As with the entomolaris, the dimensions of the paramolaris can vary from a 'mature' root with a root canal, to a short conical extension. This additional root can be separate or nonseparate. Carlsen and alexandersen describe two different types A and B. Table 5

**Table 4:** Carlsen and Alexandersen classification based on the location of the cervical part of entomolaris

<b>Type A</b>	A distally located cervical part of the entomolaris with two normal and one normal distal root components, respectively
<b>B</b>	A distally located cervical part of the entomolaris with two normal and one normal distal root components, respectively
<b>C</b>	Amesially located cervical part
<b>AC</b>	to a central location

**Table 5:** Radix paramolaris classification

<b>Types A</b>	Cervical part is located on the mesial root complex
<b>Type B</b>	Cervical part is located centrally, between the mesial and distal root complexes.

### Clinical Approach

A knee inspection of pre-operative radiograph and interpretation of particular marks or characteristics, such as an unclear view or outline of the distal root contour or the root canal, can indicate the presence of a hidden Entomolaris. To reveal the radix, another radiograph should be taken from a more mesial or distal [30 degree].

Clinical inspection of the tooth crown and analysis of cervical morphology of the roots checked by periodontal probing, give idea of an additional root.

The location of the orifice of the root canal of entomolaris access cavity shaped triangular to trapezoidal. A severe root inclination or canal curvature, particularly in the apical third of the root canal, can cause shaping aberrations such as straightening of the root canal or a ledge, with root canal transportation and loss of working length.

All cases follow up 18 months with no clinical sign and symptoms and no changes in radiograph.

### Conclusion

Root canal treatment is success when all canal is properly clean and shape up to apex. Missed canal leads to failure. Radix has a well success rate of root canal treatment if thorough knowledge of anatomy of canal orifice and canal curvature.

**Conflict of Interest:** None.

### References

1. CoutinhoFilho T, La Cerda RS, GurgelFilho ED, de Deus GA, Magalhães KM. The influence of the Surgical Operating Microscope in locating the mesiolingual canal orifice: A laboratory analysis. *Braz Oral Res* 2006;20:59-63.
2. Tu M-G, Tsai C-C, Jou M-J, Chen W-L, Chang Y-F, Chen S-Y et al. Prevalence of three rooted mandibular first molars among Taiwanese individuals. *J Endod* 2007;33:1163.
3. Gulabivala K, Anug TH, alavia, Ng YL. Root and canal morphology of Burmese mandibular molars. *Intendod J* 2001;34:359
4. Calberson FL, DeMoor RJ, Deroose CA: The radix entomolaris and paramolaris: a clinical approach in endodontics. *J Endodo* 2007;33:58.
5. Demoor RJ, Calberson FL: The radix entomolaris in mandibular first molars: an endodontic challenges *IntEndod J* 2004;37:789.
6. Sperber GH, Moneau Ji. Study of the number of roots and canals in Senegalese first permanent mandibular molars. *IntEndod J* 1998;31:112-6.
7. Pedersen PO. The East Greenland Eskimo dentition. Numerical variations and anatomy. A contribution to comparative ethnic odontology. *Copenhagen: Meddeleser Om Gronland* 1949;104:140-4.

**How to cite this article:** Nahar AB. Radix Entomolaris and paramolaris, Case reports. *Indian J Conserv Endod* 2019;4(1):58-61.