

Surgical single visit apexification with biodentine and single visit root canal treatment - A case report

B. K. Biswas^{1*}, Chiranjan Guha²

¹CEO, ²Head, ^{1,2}Dept. of Endodontics, ^{1,2}Avinash Institute of Craniofacial and Reconstructive Surgery (AICRS), Kolkata, West Bengal India

*Corresponding Author: B. K. Biswas

Email: doc135798@yahoo.co.in

Abstract

Traumatic injuries are very common in both adolescence and in adults. Traumatic injuries of the permanent teeth often results in crown fracture with or without associated fracture of root. Inflammatory periapical lesion should be initially treated with conservative nonsurgical procedures.(Lin.et al).

A 23 year old male patient reported to the department of Conservative Dentistry and Endodontics of AICRS with the chief complaint of broken tooth and pain in upper front teeth region. Non surgical single visit endodontic treatment done in 11 and 12. Single visit apexification in 21 with the help of Bio-dentine had also been done on same visit. In this clinical study, Bio-dentine showed promising result when used for apexification of non-vital immature tooth with open apex. Single visit endodontics proved to be effective for the management of periapical lesion.

Keywords: Traumatic injuries, Periapical lesion, Apexification, Single visit, Non surgical, Bio-dentin.

Introduction

Traumatic injuries are very common in both adolescence and in adults.¹ Traumatic injuries of the permanent teeth often results in crown fracture with or without associated fracture of root. Maxillary anteriors are very much affected in this case. The most frequently involved teeth are the maxillary incisors with a percentage of 75% in permanent teeth.(Majorana A et al, Dental Traumatology,2002 Apr;18(2). If it is left untreated it can lead to open apex and periapical pathologies.¹⁰

Inflammatory periapical lesions should be initially treated with conservative nonsurgical procedures (Lin et al). Various non-surgical methods have been used to treat periapical lesions (Shah 1988, Hoen et al. 1990, Loushine et al. 1991, C alis kan 2004, Kur's at et al. 2007, Metzger et al. 2009)

1. Single or Multiple visit non surgical endodontic treatment.
2. Aspiration and irrigation technique.
3. Lesion sterilization and Tissue repair therapy
4. Apexum procedure.
5. Non-surgical decompression technique.

In case of non-surgical procedure if the patient is not symptomatic, in that case surgical management is needed.

Case Report

A 23 year old male patient reported to the department of Conservative dentistry and Endodontics of AICRS, Kolkata (West Bengal) with the chief complaint of broken tooth and pain in upper front teeth region.

The patient faced two separate road traffic accidents and got trauma affecting the same region of teeth, first one was at the age of 9 years and the second one was 21years. But in both incidences patient did not receive any treatment.

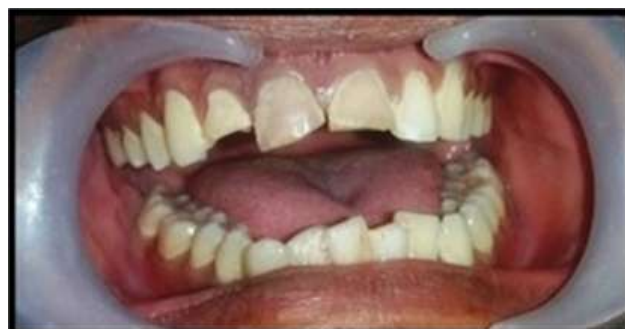

Fig. 1: Pre-operative clinical picture

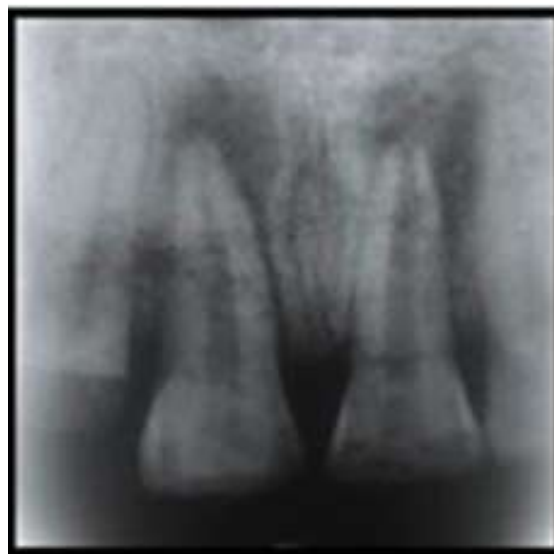

Fig 2: Pre-operative IOPA radiograph

Clinical Examination

Table 1: Clinical Examination

Tooth Number	Presence & Type of Fracture	Tender on Percussion	Soft Tissue Palpation	Peridental Tissue Profile
11	Ellis Class 1	No	NAD	Grade II mobile
21	Ellis Class 1	No	NAD	NAD
12	Ellis Class 3 with mobile palatal fragment	No	NAD	NAD

Table 2: Radiographical examination

Tooth Number	Loss of enamel and dentin	Exposure of pulp	Periapical radiolucency	Open apex
11	Present	Absent	Approximately 6mm (Longest diameter)	Absent
21	Present	Absent	Approximately 7mm (Longest diameter)	Present
12	Present	Present	Absent	Absent

Table 3: Clinical follow up

Visit Frequency	Tooth Number	Palpation	Percussion	Periodontal Tissue Profile
15 days	11, 21, 12	X	X	X
1 month	11, 21, 12	X	X	X
2 month	11, 21, 12	X	X	X

Table 4: Radiographical follow-up after 15 days, 1 month, 2 months

Size of radiolucency	Calcific barrier formation	Appearance of bony trabeculae	Width of periodontal ligament space	Breakdown of lamina dura
Unchanged	Present	Absent	Normal	Nil
Unchanged	Present	Present	Normal	Nil
Reduction in size 1mm.	Present	Present	Normal	Nil

Diagnosis and Treatment Plan

Diagnosis

Treatment Plan

1. Removal of mobile palatal fragment of 12.
2. Splinting to be done with stainless steel wire (16 gauge) and composite resin from canine to canine region of maxillary anterior teeth.
3. Non-surgical single visit endodontic treatment done in 11 and 12.
4. Single visit apexification in 21 with the help of Biodentine.

Methodology

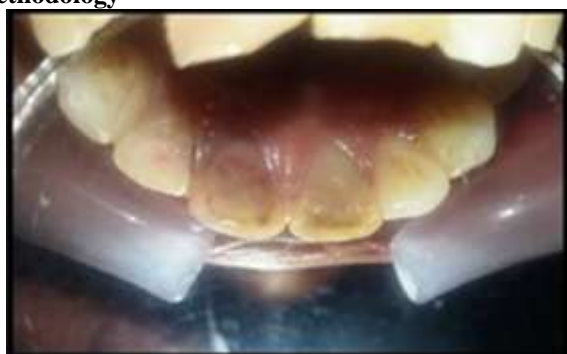

Fig. 3: Pre-operative intra-oral picture




Fig. 4: Fracture fragment

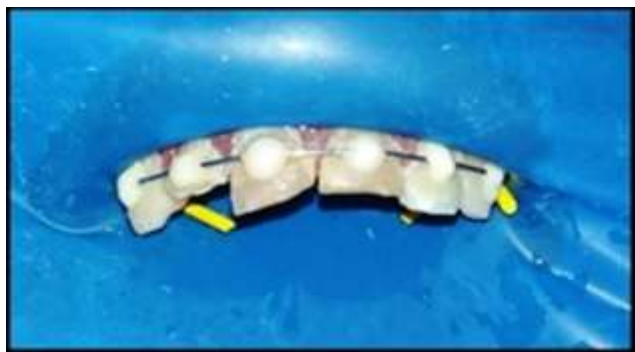

Fig. 5: Splinting done from canine to canine region under rubber-dam isolation

Access cavity preparation was done in 11 and 12 under rubber-dam isolation. Working length was determined with the help of apex-locator and was confirmed by intra-oral periapical radiograph.

Canal shaping was done by crown-down technique.

2 ml of 3% Sodium hypochlorite as irrigant was used after each instrumentation.

After master-cone selection, 4ml of 17 % EDTA was used, followed by 6 ml of Normal saline.

Final irrigation was done with 4ml of 2% chlorhexidine.

Canal was dried using sterile paper points.

AH-26 sealer and gutta-percha was used for obturation with lateral compaction technique.

Access cavity restoration was done with Glass ionomer cement. (Root canal irrigants, Kandaswamy and NagendraVenkateshbabu, *J Conserv Dent* 2010;13(4):256–64.

Access cavity preparation was done in 21 under rubber-dam isolation.

Canal cleaning and shaping was done with crown-down technique.

A 4 mm diameter of absorbable gelatine sponge (Abgel) was inserted in the canal with the help of pluggers to serve as an apical barrier.⁴

Biodentine (Septodont, St. Maurdes-Fossés, France) was mixed to a paste like consistency in a triturator and delivered to the canal using amalgam carrier and condensed with Schilder's pluggers.

A post operative radiograph was taken and the access cavity was closed with Glass ionomer cement.

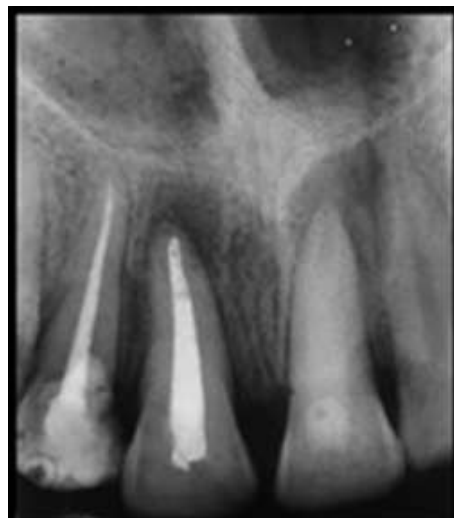

Fig. 6: Post-obturation IOPA radiograph

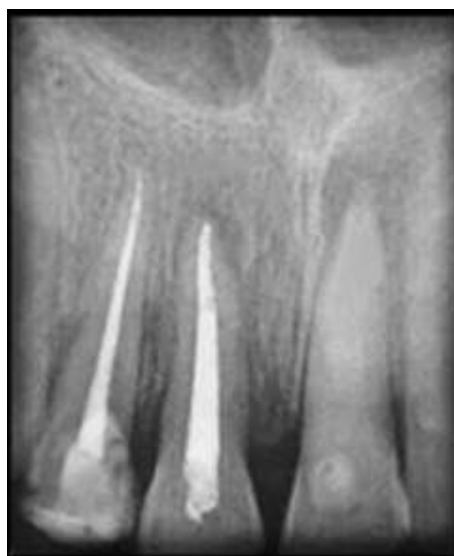

Fig. 7: After 2 months follow-up

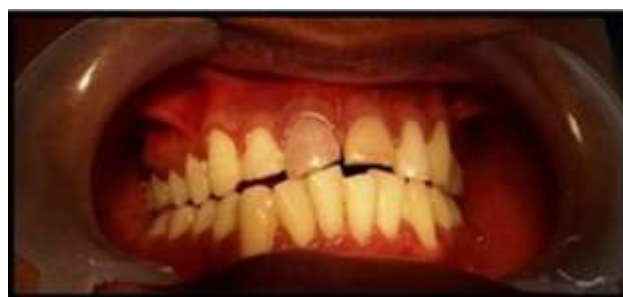

Fig. 8: Clinical follow-up After 2 months follow-up

Discussion

The goal of apexification is to obtain an apical barrier to prevent the passage of toxins and bacteria into periapical tissues from the root canal.

Single visit Apexification with Biodentine requires significantly less time, superior biocompatibility and sealing ability and is less cytotoxic than other materials currently being used in pulpal therapy.⁸

Kokate and Pawar conducted a study that compared the microleakage of glass ionomer cement, MTA, and Biodentine™ when used as a retrograde filling material and concluded that Biodentine™ exhibited the least microleakage when compared to other materials used.

The only limitation of Biodentine is that it cannot be used in the presence of moisture.⁷

In the present case, the use of Abgel as apical matrix not only served in limiting the Biodentine to root canal but also provided an isolated environment for setting of Biodentine.

Periapical pathology is a host defence mechanism to micro-organisms present in the root canal and endodontic treatment attempts to eradicate the micro-organisms from the root canal system and thus promoting periapical healing.¹⁰

In recent years, single-appointment endodontics has gained increased acceptance.

The scientific basis for the single visit endodontics is that the residual micro-organisms are rendered harmless by entombing them by complete obturation immediately after cleaning and shaping the root canal space in the same visit.

Guttman et al. (2004), in a clinical study, found that single visit RCT was as successful as multiple visit RCT in teeth with vital as well as in teeth with non-vital pulp associated with or without periapical radiolucencies.

The advantages of single visit endodontic include reduction in time and cost of treatment and prevention of inter-appointment flare ups and as well as low incidence of postoperative pain when compared to multiple visit treatment.¹¹

This case report emphasizes the novel approach of using Biodentine to achieve single visit apexification of the cases with an open apex followed by periapical lesion and also the prognosis of single visit endodontic treatment of teeth associated with periapical lesion.

Conclusion

In this clinical study, Biodentine showed promising result when used for apexification of non-vital immature tooth with open apex. Single visit endodontics proved to be effective for the management of periapical lesion.

Conflict of Interest: None.

Reference

1. Pathways of The Pulp, Cohen.
2. Grossman's Endodontic Practice.
3. Bogen G and Sergio Kuttler S. Mineral Trioxide Aggregate obturation: A Review and Case Series. *J Endod.* 2009;35:777–90.
4. Elumalai D, Kapoor B, Tewrai RK, Mishra SK. Comparison of mineral trioxide aggregate and biodentine for management of open apices; *J Interdiscip Dent* 2015;5(3).
5. Jaiswal S, Gupta S, Sawani S, Gupta J, People's Journal of Scientific Research July 2014; Vol. 7, Issue 2.
6. Chaudhry S, Yadav S, Oberoi G, Talwar S, and Verma M, *Int J Dent Sci Res* 2016;4;(3)58-61. doi:10.12691/ijdsr-4-3-6.
7. Khetarpal A, Chaudhary S, Talwar S, Verma M. Endodontic management of open apex using Biodentine as a novel apical matrix. *Indian J Dent Res* 2014;25:513-6
8. Figini L, Lodi G, Gorni F, Gagliani M. Single versus multiple visits for endodontic treatment of permanent teeth. *Cochrane Database Syst Rev* 2007;4. Art. No.: CD005296. DOI:10.1002/14651858.CD005296.pub2.
9. Kalhor FA and Mirza AJ, *Journal of the College of Physicians and Surgeons Pakistan* 2009;19(7): 410-12.
10. Fernandes M, Ataide Id. Nonsurgical management of periapical lesions. *J Conserv Dent* 2010;13:240-5.
11. Ipsita Maity, N. Meena, and Kumari RA. Single visit nonsurgical endodontic therapy for periapical cysts: A clinical study, *Contemp Clin Dent* 2014;5(2):195–202.

How to cite this article: Biswas BK, Guha C. Surgical single visit apexification with biodentine and single visit root canal treatment - A case report. *Indian J Conserv Endod* 2019;4(2):62-5.