

## Retrieval of a separated instrument extending periapically using ultrasonics: A case report

Pritesh Kisanlal Agarwal<sup>1\*</sup>, Bhavesh Ahir<sup>2</sup>, Alisha B Wani<sup>3</sup>

<sup>1,3</sup>Senior Lecturer, <sup>2</sup>Reader, Dept. of Conservative and Endodontics, ACPM Dental College, Dhule, Maharashtra, India

### Abstract

Instrument separation is a nightmare for dentists. It blocks the canal preventing further cleaning and shaping. This may lead to failure of root canal treatment. This case report presents successful management of instrument separation in mesiolingual canal of mandibular first molar. Retrieval of an instrument fractured below the curvature and extending periapically is a very difficult task. Ultrasonic technique along with dental operating microscope was used in this case.

**Keywords:** Ultrasonics, Dental operating microscope, Instrument separation.

### Introduction

Instrument separation is one of the most unwanted endodontic mishaps. It blocks the canal preventing further cleaning and shaping of the root canal. Incomplete debridement may lead to root canal failure. Also it may cause irritation to the periapical tissues when the separated fragment extends periapically.<sup>1</sup> Instrument separation is classified as failure due to cyclic flexural fatigue or torsional failure or a combination of both.<sup>2</sup>

Various reasons for instrument fracture are inadequate straight line access, forcefully pushing of the instrument in the canal, overuse, filing without lubricant, manufacturing defects, canal anatomy, absence of glide path, speed, torque etc.<sup>2,3</sup>

Various treatment options for instrument separation are instrument bypass, obturation and follow up, retrieval, periapical surgery, reimplantation and extraction.

In clinical studies, the incidence of instrument separation has been reported from 0.39%–5%.<sup>4</sup> Various methods of instrument retrieval have been discussed in past. This case report discusses successful management of instrument separation extending periapically in the mesial canal of mandibular first molar.

### Case Report

A 35 year old male patient reported to our clinic with a chief complaint of pain with 36 (Permanent left mandibular first molar). The patient gave history of previously initiated root canal treatment with 36. On clinical examination cotton pellet was seen in access cavity of 36 without any closed dressing. The tooth was tender on percussion.

IOPA showed instrument separation in the mesial canal extending beyond apex (Fig.1A). Periodontal ligament widening and break in the continuity of lamina dura was seen with mesial root of 36. Also accessory root (radix entomolaris) was seen. The patient did not know about the

separation. We informed him about the problem and various treatment options; 1) instrument retrieval, 2) periapical surgery 3) reimplantation and 4) extraction.

The patient wanted retrieval or extraction of teeth due to psychological fear factor. After his consent, we decided to go for instrument retrieval. The procedure and complications associated with it were explained to the patient.

Local anesthesia with 2% lidocaine and 1:80000 epinephrine was established and rubber dam isolation done. The separation was confirmed in mesiolingual canal with hand files and radiograph. Other canal orifices were blocked with cotton pellet. Coronal flaring was done with Gates Glidden drills. Initially the instrument was bypassed with the help of hand files and liquid EDTA and retrieval was attempted by braiding technique with the help of H files. But the file could not be retrieved. Then it was decided to go for ultrasonic method. Circumferential staging platform was created with the help of modified Gates Glidden drills. The Gates Glidden drills were modified by sectioning them at maximum cross sectional diameter perpendicular to the long axis. Circumferential space was created around the separated instrument by troughing of dentin with ultrasonics. Following this ET 25 tip from Satelec was used to remove the instrument by vibrating the tip in the space created in anticlockwise direction. In between, the position of file was checked with radiographs multiple times to confirm whether the fragment is not pushed apically. After few minutes of vibrations the instrument popped out of the canal (Fig. 2 A&B). This was further confirmed in IOPA (Fig. 1B). Absence of root perforation was confirmed with apex locator and paper point. The access opening was modified and the missed distolingual canal was also located.

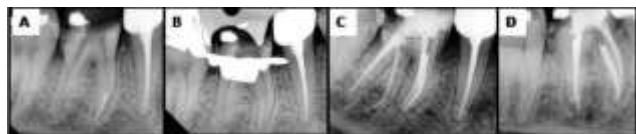Working length was determined with apex locator and confirmed with radiograph. Initial hand filing was done with hand k files followed by neo endo rotary files. Intermittent

\*Corresponding Author: Pritesh Kisanlal Agarwal, Dept. of Conservative and Endodontics, ACPM Dental College, Dhule, Maharashtra, India

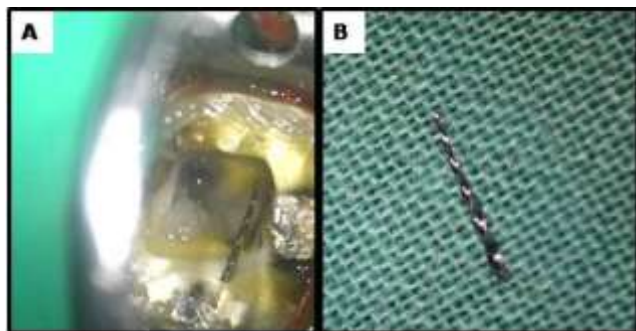
Email: [drpritesh87@gmail.com](mailto:drpritesh87@gmail.com)

<http://doi.org/10.18231/ijce.2019.025>

irrigation was done with 5 % sodium hypochlorite and 17 % EDTA. Obturation was done by warm vertical compaction and sealapex sealer (Fig. 1C & D).



**Fig. 1:** Intraoral radiographs: (A) Preoperative; (B) After instrument retrieval; (C) Postoperative; (D) Postoperative at different angulation.



**Fig. 2:** Clinical Pictures: (A) Instrument with access opening and other canal orifices blocked with cotton; (B) Retrieved instrument fragment.

## Discussion

Instrument separation is an unwanted and frustrating endodontic mishap. With the advent of rotary NITI files, incidence of instrument separation has increased.<sup>5</sup> Various factors such as length of the retained instrument fragment, position, canal anatomy, clinical diagnosis, presence or absence of periapical pathosis, dentin thickness should be assessed before treatment planning.<sup>6</sup>

A retained fractured instrument *per se* generally did not adversely affect endodontic case prognosis.<sup>7</sup> The most important prognostic factor for instrument separation cases is presence or absence of periapical pathology.<sup>7-9</sup> Presence of periapical pathology negatively affects the prognosis.<sup>7-9</sup> Whenever the fractured fragment extends beyond the apex, it is imperative to retrieve the fragment.<sup>10</sup> It can act as a niche for bacterial accumulation leading to failure.<sup>11</sup>

Also due to presence of periapical infection, tenderness on percussion and psychological fear factor of patient, instrument retrieval was essential in this case. Patient was not ready for periapical surgery. Reimplantation was not opted as the tooth had extra root and was root canal treated. Hence chances of fracture were there during extraction. Hence, instrument retrieval was the only option left to save the tooth. All the possible complications that can happen were explained to the patient and it was decided to attempt orthograde removal of the fractured fragment.

In our case separation might have occurred due to forcing the file to an arbitrary length beyond the apex. It was a challenging case as the fractured fragment was extending in the periapical region and the presence of

curvature.<sup>10</sup> Initially the instrument was bypassed and tried to remove by the braided technique because it does not involve unnecessary removal of dentin. But it was unsuccessful. Hence we decided to go for ultrasonic and microscope as it is considered to be the most conservative, universally accepted and investigated technique.<sup>12</sup> Dental operating microscope provides excellent visibility of the separated instrument and increases the success rate of retrieval. Use of microscope also reduces the chances of complications such as perforation.<sup>13</sup>

Hence, a blend of sound knowledge of root canal anatomy and use of advanced technologies such as dental operating microscope and ultrasonics has lead to successful management of this case.

## Conclusion

Every case of instrument separation is a unique case. No single standard technique is effective in all cases. Thorough knowledge of tooth anatomy and technologies is essential for successful management of a case. The chances of success should be balanced against potential complications. However, the best antidote for instrument separation is prevention.

## Source of Funding

None.

## Conflict of Interest

None.

## References

- Heydari A, Rahmani M, Heydari M. Removal of a broken instrument from a tooth with apical periodontitis using a novel approach. *Iran Endod J* 2016;11(3):237-40.
- Parashos P, Messer HH. Rotary NiTi instrument fracture and its consequences. *J Endod* 2006;32(11):1031-43.
- Natanasabapathy V, Sundar S, Koteeswaran V. Retrieval of fractured NiTi rotary instrument using ultrasonics and file braiding technique under surgical operating microscope. *Endodontology* 2017;29:65-8.
- Nevares G, Cunha RS, Zuolo ML, Bueno CE. Success rates for removing or bypassing fractured instruments: a prospective clinical study. *J Endod* 2012;38(4):442-4.
- Gandhi N, Gandhi S, Bither S. Displacement of endodontic instruments in inferior alveolar canal. *Indian J Dent Res* 2011;22(5):736.
- Rahimi M, Parashos P. A novel technique for the removal of fractured instruments in the apical third of curved root canals. *Int Endod J* 2009;42(3):264-70.
- Al – Zahrani MS, Al – Nazhan S. Retrieval of separated instruments using a combined method with a modified vista dental tip. *Saudi Endod J* 2012;2:41-5.
- Gandevivala A, Parekh B, Poplai G, Sayed A. Surgical removal of fractured endodontic instrument in the periapex of mandibular first molar. *J Int Oral Health* 2014;6(4): 85-8.
- Mantri S. Management of fractured root canal treated mandibular molar with separated endodontic instrument extending in periapical region. *SAGE Open Med Case Rep* 2018;6:1-3
- Sheethi K V, Sheoran K, Singh T V. Surgical removal of fractured endodontic instrument extending beyond the periapex

- of mesiobuccal root of maxillary second molar through the maxillary sinus. *J Clin Diagn Res* 2017;11(10): ZD04-ZD05.
11. Noorani T, Asif J, Ghani N. Surgical endodontics to manage a separated instrument: A case report. *Dent Update* 2017;993-7.
  12. McGuigan MB, Louca C, Duncan HF. Clinical decision – making after endodontic instrument fracture. *Br Dent J* 2013;214(8):395-400.
  13. Singh P, Thomas P, Sreeram SR, Vaisakh NG. Retrieval of a separated instrument using two different techniques: Case reports. *J Dent Med Sci* 2014 Dec. ;13(12) :18-20.

**How to cite this article:** Agarwal PK, Ahir B, Wani AB. Retrieval of a separated instrument extending periapically using ultrasonics: A case report. *Indian J Conserv Endod* 2019;4(3):105-7.